



**DATE PRESENTING CLINICAL SIGNS**

11.13.25 History: 7/31/25- Presented for progressive non-productive, hacking cough and 5.5lbs of weight loss since January. Started on tapering dose of prednisone 20mg and improved. 9/24/25 started having an intermittent non-productive cough. Progressed to a productive, persistent cough on 9/26 when prednisone was started 1mg/kg PO BID. Cough has decreased in frequency and is now non-productive. Responded well to another tapering dose of prednisone.

**PATIENT**

Harper Kuhn

**SPECIES**

Canine

**BREED**

Bernese Mountain Dog

**SEX**

FS

**AGE**

7.15.17

**WEIGHT**

70.2lbs

**INTERPRETED BY**

Maggie Machen Lamy,  
DVM, DACVIM  
(Cardiology)

**HOSPITAL NAME**

Banfield Pet Hospital  
Timonium

**REFERRING VET**

Dr. Falkowski

**INVOICE**

45743

-CXR report: normal heart size. Possible PA enlargement.  
-Pertinent abnormal PE/Chem/CBC/UA Results: Superchem/CBC WNL. UA- unremarkable, 4Dx negative.  
-Current medications: Prednisone 20mg PO EOD since 10/28/25, Fluticasone inhaler 110mcg/puff 2 puffs BID since 11/1/25  
-Sedation used: Not required to complete full diagnostic ultrasound.  
-Pertinent previous ultrasound results: No previous.  
-STAT: Not requested.  
-Imaging performed by: Stephanie Warga RDACS, RVT.

**ECHOCARDIOGRAM FINDINGS**

2D, m-mode, color flow and doppler imaging is available. Normal mitral valve leaflets with no prolapse into the left atrial lumen. No mitral regurgitation with no left atrial dilation. Normal LV diameter with adequate myocardial function. The tricuspid valve appears normal with trace tricuspid regurgitation. Normal right atrial and ventricular diameter and morphology indicating no overt evidence of pulmonary arterial hypertension. The pulmonic and aortic valves are normal in morphology and mobility. Normal pulmonic and aortic outflow velocities with laminar flow. No obvious aortic or pulmonic insufficiency. No pericardial or pleural effusion noted. No obvious cardiac masses.

**CARDIAC CHART**

CANINE CARDIAC PARAMETERS	MR VMAX (m/s)	TR VMAX (m/s)	LA/AO (Boon method)	LA/AO (Heart Base; Swe)	FS (%)	EF (%)	EPSS (cm)
NORMAL PARAMETER	4.5-5.5	<2.7	1.3	<1.6	28-40	40-100	<0.6
PATIENT		2.7	NM	1.2	40	70	NM
CANINE CARDIAC PARAMETERS	HR (BPM)	AV VMAX (m/s)	PV MAX (m/s)	BODY WEIGHT (kg)	LA 2D short axis Base view (cm)	LVIDd Avg; 2D and m-mode short axis (cm)	LVIDs Avg; 2D and m-mode short axis (cm)
NORMAL PARAMETER	50-100	0.7-1.7	0.7-1.6	BELOW	BELOW	BELOW	BELOW
PATIENT	120	1.4	1.1	31.8	2.9	4.2	2.6
*Normal chamber parameters expressed as a mean value (SD)				3	1.27 (5.3)	2.46 (2.46)	1.36 (5.5)
<b>BODY WEIGHT DEPENDENT PARAMETERS</b>				5	1.40 (4.5)	2.74 (5.2)	1.60 (4.7)
*Note: All measurements based upon multi-modal images and methods. An average value is reported.				10	1.50 (3.8)	3.27 (3.5)	2.06 (3.1)
				15	1.83 (2.0)	3.71 (2.4)	2.43 (2.1)
				20	2.02 (1.9)	4.14 (2.2)	2.80 (2.0)
				25	2.18 (2.4)	4.48 (2.9)	3.10 (2.5)
				30	2.33 (3.3)	4.83 (3.9)	3.39 (3.4)
				35	2.48 (4.3)	5.17 (5.0)	3.69 (4.5)
				40	2.62 (5.2)	5.48 (6.1)	3.96 (5.4)
				50	2.88 (7.1)	6.07 (8.3)	4.46 (7.4)

Adapted from June Boon, Veterinary Echocardiography, 1998  
Rishniw M and Hollis NE, J Vet Intern Med 2000; 14:429-435  
Hansson et al, Vet Rad and Ultrasound 2002  
Bonagura et al. Echocardiography: principles of interpretation, Vet Clin North Am 15:1177, 1995

### **INTERPRETATION OF THE FINDINGS & FURTHER RECOMMENDATIONS**

Overtly normal cardiac dimensions and function, with no obvious dysfunction or dilation of the left heart. No significant valvular leaks are visualized, and no evidence of pulmonary hypertension.

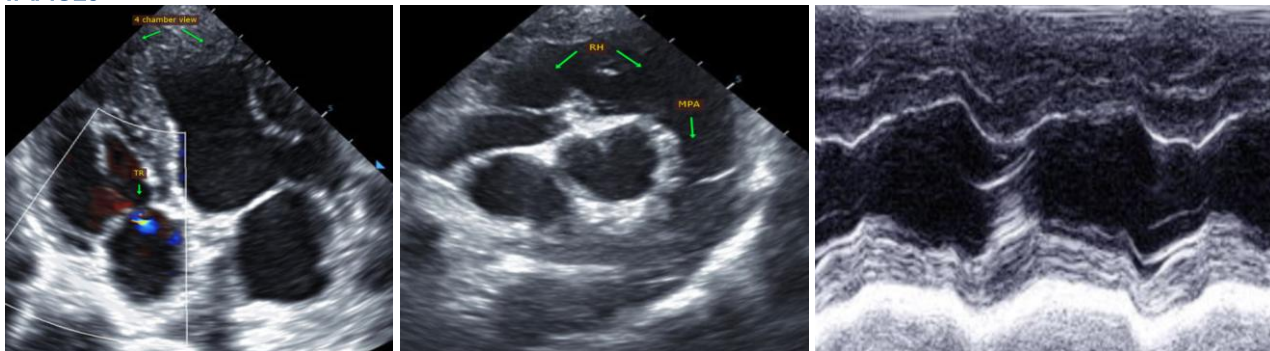
Given these findings, radiographic appearance is likely a normal variant. Early pulmonary hypertension is difficult to rule out and monitoring is advised, particularly should any associated clinical signs of PAH develop (exertional syncope or dyspnea).

No cardiac medications are indicated at this time as the cough is certainly non-cardiac in origin. Continued work up for infectious/inflammatory respiratory causes is recommended. Options include Baytril or similar antibiotic, anti-inflammatory prednisone, aggressive hydrocodone, etc. If refractory, may consider TTW/BAL for further information.

Monitor for development of a heart murmur, acutely progressive cough, labored breathing, exercise intolerance or collapse episodes.

Chronic respiratory issues can lead to pulmonary hypertension if poorly controlled and a recheck echocardiogram is recommended should any exertional syncope/dyspnea occur, or a murmur be noted in the future.

### **IMAGES**



**The information and recommendations provided are based on the images presented by the referring veterinarian. No evaluation can be communicated regarding pathology that was not visible in the image/video clips provided.**

Thank you for this referral. This report was generated using transcription software, and minor dictation errors may be present. If the clinical or image interpretation does not parallel your findings or if I can be of any further assistance, please contact me.

**Maggie Machen Lamy, DVM**  
**Diplomate of the American College of Veterinary Internal Medicine (Cardiology)**  
**info@sonopath.com**